



Neurotechnology Applied to Medicine. Analysis of Patients Undergoing Neuro Endoscopy in Triventricular Obstructive Hydrocephalus

Javier Gonzalez-Argote^{1,2*}

¹ Facultad de Medicina y Ciencias de la Salud, Universidad Abierta Interamericana, Ciudad Autónoma de Buenos Aires, Argentina.

² Fundación Salud, Ciencia y Tecnología, Ciudad Autónoma de Buenos Aires, Argentina.

Correspondence: E-mail: jargote@saludcyt.ar

ABSTRACT

Hydrocephalus is the condition that has benefited the most from neuroendoscopy and is largely responsible for its emergence. The purpose of this study was to evaluate the application of endoscopic third ventriculostomy to treat obstructive triventricular hydrocephalus in the Neurosurgery Department. A descriptive study was conducted in a hospital in the Buenos Aires suburbs involving patients admitted to the neurosurgery department diagnosed with obstructive triventricular hydrocephalus. We reviewed 37 male patients (75.5 %) and 12 female patients (24.5 %). Hydrocephalus grade II was observed in 87.7%, and only 16.3% were associated with transependymal flow and hydrocephalus grade III. These imaging signs allowed us to diagnose the type of obstructive triventricular hydrocephalus, as well as to have an initial reference for postoperative evaluation and follow-up of diagnosed patients, relying on the dimensions of the third ventricle, Evans index, and Morlan scale for hydrocephalus grade, enabling quantification of these signs during their progression.

ARTICLE INFO

Article History:

Submitted/Received 02 May 2023

First Revised 22 Jun 2022

Accepted 31 Aug 2023

First Available online 01 Sep 2023

Publication Date 01 Dec 2023

Keyword:

Hydrocephalus,
Neuroendoscopy,
Neurotechnology applied,
Triventricular obstructive
hydrocephalus.

1. INTRODUCTION

Hydrocephalus is cerebrospinal fluid (CSF) accumulation within the intracranial compartment due to a disorder in its production, circulation, absorption, or a combination of these factors (Kahle *et al.*, 2016). In hydrocephalus, the increase in CSF goes beyond physiologically permissible limits within the ventricular system and the subarachnoid space due to disrupting its natural dynamics. This situation leads to severe and progressive neurological deterioration in the patient, necessitating mandatory medical assistance (Hochstetler *et al.*, 2022). Hydrocephalus can be congenital or acquired. Congenital hydrocephalus presents at birth and can be caused by environmental influences during fetal development or genetic predisposition. Acquired hydrocephalus develops at birth or some points afterward (Becerra & Páez, 2022; Pérez, 2022; Silva *et al.*, 2023).

This type of hydrocephalus can affect people of all ages. It can be caused by an injury or a disease that leads to increased CSF volume, usually secondary to an obstruction (Karimy *et al.*, 2020; Novoa-Rojas & Báez-Alarcón, 2023; Salazar *et al.*, 2023). Childhood hydrocephalus poses a significant burden for all countries, especially in underdeveloped regions, where the proportion is higher than in countries with developed healthcare levels. In Latin America, the most common causes of hydrocephalus are linked to poor prenatal care and neonatal sepsis, meningitis, and ventriculitis, resulting in damage to the CSF drainage system (Apra *et al.*, 2019; Wang *et al.*, 2020). Hydrocephalus is the condition that has benefited the most from neuroendoscopy and is largely responsible for its emergence (Morales *et al.*, 2023). Specifically, in obstructive triventricular hydrocephalus, pre-mamillary third ventriculostomy is the most frequent neuroendoscopic procedure (Oliveira *et al.*, 2019; Rodríguez-Portelles *et al.*, 2023). It involves endoscopic perforation of the floor of the third ventricle, aiming to establish communication between the ventricular system and the basal cisterns of the brain, thereby resolving the obstruction at the level of the cerebral aqueduct or the fourth ventricle (Nakajima *et al.*, 2021; Saltos *et al.*, 2023; Verdesoto *et al.*, 2023).

Third ventriculocisternostomy is the procedure of choice in patients with obstructive or non-communicating hydrocephalus, regardless of etiology, with a sufficiently dilated third ventricle (more than 10 mm) to allow for endoscope use and adequate capacity for CSF reabsorption in the subarachnoid space (Catrambone & Ledwith, 2023; Jurado *et al.*, 2023; Krejčí *et al.*, 2021; Ramírez & Ruetti, 2023). Patients with hydrocephalus due to congenital stenosis of the Sylvian aqueduct and tumor obstruction of CSF circulation in any location beyond the Monro foramina (thalamic tumors, pineal tumors, tectal region, posterior fossa, etc.) constitute the primary indication for the procedure. Following these criteria, therapeutic success exceeds 90%, with failures caused solely by technical issues (Mejías *et al.*, 2022). The objective of this study was to evaluate the application of endoscopic third ventriculostomy to treat obstructive triventricular hydrocephalus in the Neurosurgery Department.

2. METHODS

A descriptive study was conducted in a hospital in the Buenos Aires suburbs involving patients admitted to the neurosurgery department diagnosed with obstructive triventricular hydrocephalus. A study group was created, including those patients who underwent surgical intervention through the neuroendoscopic third ventriculostomy procedure.

The study population consisted of 49 patients diagnosed with obstructive triventricular hydrocephalus, treated in the neurosurgery department, who underwent neuroendoscopic third ventriculostomy, forming the study group. The sample was selected based on inclusion and exclusion criteria. Inclusion Criteria include:

- (i) Patients diagnosed with obstructive triventricular hydrocephalus based on clinical and imaging findings.
- (ii) Patients with obstructive triventricular hydrocephalus regardless of its cause.
- (iii) Patients who agreed to undergo endoscopic surgery as treatment.

Exclusion Criteria include:

- (i) Patients whose study was not completed.
- (ii) Patients who declined to undergo endoscopic treatment.

For methodology and intervention, upon arrival at the neurosurgery department through the emergency room or outpatient consultation, patients underwent a detailed neurological interview and physical examination. This was complemented by fundus examination and imaging studies. Based on these elements, patients were either hospitalized for urgent neuroendoscopic surgery, depending on their neurological condition, or, if feasible, elective surgical treatment was planned. Using computed tomography (CT) images, the dilation of the lateral and third ventricles was determined. The EVANS index (**Figure 1**) was calculated, which involves the greater diameter of the frontal horns of the lateral ventricles and the greater biparietal diameter being more than 30% of the diameter of the third ventricle. The degree of hydrocephalus was assessed using the Marlon scale (**Figure 2**), considering the presence of the temporal horns of the lateral ventricles, trans ependymal flow, decreased subarachnoid space, and other imaging elements indicating obstructive hydrocephalus. Furthermore, this imaging study also aided in diagnosing the possible etiological cause of obstructive hydrocephalus.

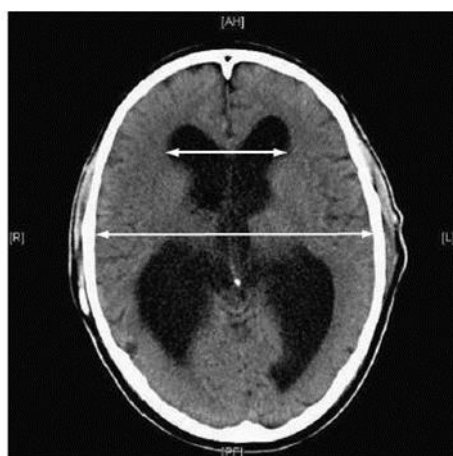

Figure 1. Measurement of ventriculomegaly on axial CT.

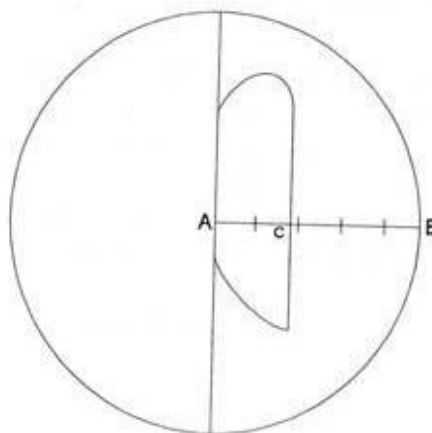


Figure 2. Application of the Marlon scale.

Once diagnosed and in compliance with the surgical indications for endoscopic surgery, the patient underwent preoperative studies. Depending on the patient's condition, it was announced for elective or emergency surgery, performing neuroendoscopic treatment. In the case of triventricular obstructive hydrocephalus, fenestration of the floor of the III ventricle was performed directly, and in cases where the cause of obstructive hydrocephalus was an intraventricular tumor or cyst, it was treated with endoscopic resection or sampling for anatomopathological study. All these patients were given informed consent before surgery, as a legal document authorizing the neurosurgical procedure (Ruiz *et al.*, 2023).

The patients were recovered in the first 24 hours in the intensive care ward and then transferred to the neurosurgery ward. After the first 72 hours of the postoperative period, CT was indicated, if it was not previously necessary due to some complication depending on the surgical technique. For ethical aspects, medical research is subject to ethical standards that serve to promote respect for all human beings and to protect their health and individual rights. Some populations subjected to research are vulnerable and need special protection. This research has complied with the basic principles of medical bioethics and the Declaration of Helsinki (Diaz & Albanese, 2023).

3. RESULTS AND DISCUSSION

Forty-nine patients with triventricular obstructive hydrocephalus underwent endoscopic third ventriculostomy (TVE). In terms of age groups, those under 20 years of age predominated with twelve patients (24.5 %), followed by the 21 to 30 years age group with eleven patients (22.4 %), the 31 to 40 years age group with eight patients (16.3 %); the 41 to 50 years age group with ten patients (20.4 %), the 51 to 60 years age group with five patients (10.3 %), and those over 60 years of age with only three patients (6.1 %). Most of the literature reviewed studies pediatric patients since this pathology is more frequent in this stage of life (45). We reviewed 37 male patients (75.5 %) and 12 female patients (24.5 %) (see **Table 1**).

Table 1. Symptoms and clinical signs of patients with triventricular obstructive hydrocephalus.

Symptoms and clinical signs	N	%
Headache	49	100
Vomiting	27	55.1
Papilledema	33	67.3
Alteration of the level of consciousness.	13	26.5
Alteration of the upper psychic sphere.	4	8.2
Alteration of psychomotor development	5	10.2
Motor defect	7	14.3
Macrocephaly	5	10.2

Table 1 shows the clinical symptoms and signs present in patients with triventricular hydrocephalus, with headache being the symptom present in 100% of patients, followed by papilledema in 67.3%, vomiting in 55.1%, altered level of consciousness in 26.5%, motor defect in 14.3%, altered psychomotor development and macrocephaly in 10.2% and only alteration of the upper psychic sphere in 8.2%. Symptoms and signs of presentation and evolution over time of hydrocephalus depend on the age of the patient (Lefevre *et al.*, 2023; Sulibele *et al.*, 2023; Tandon, 2021).

(i) In children:

- An extraordinarily large head or rapid increase in head circumference.

- Vomiting, sleepiness, irritability, downward eye deviation ("sunset"), and/or seizures.
- (ii) In older children or adults:
- Headaches.
 - Nausea
 - Papilledema
 - Downward drifting of the eyes
 - Balance problems
 - Blurred vision or diplopia (double vision)

Table 2 presents the imaging signs found in patients with obstructive triventricular hydrocephalus, where decreased subarachnoid space, Evans index greater than 0.30, third ventricle greater than 10 mm, and dilation of the lateral and third ventricles were present in 100% of the patients. Hydrocephalus grade II was observed in 87.7%, and only 16.3% were associated with transependymal flow and hydrocephalus grade III. These imaging signs corresponded to those described in the reviewed literature. These imaging signs allowed us to diagnose the type of obstructive triventricular hydrocephalus, as well as to have an initial reference for postoperative evaluation and follow-up of diagnosed patients, relying on the dimensions of the third ventricle, Evans index, and Morlan scale for hydrocephalus grade, enabling quantification of these signs during their progression. Hydrocephalus grades are determined using the Morlan scale (Cuétara *et al.*, 2021; Hidalgo *et al.*, 2022; Jiménez *et al.*, 2022; Tiban & Coronado, 2023).

Table 2. Imaging signs in patients with triventricular obstructive hydrocephalus.

Imaging signs	N	%
Decreased subarachnoid space	49	100
Evans index greater than 0.30	49	100
III ventricle greater than 10 mm	49	100
Dilatation of lateral ventricles and III ventricle	49	100
Trans ependymal flow	8	16.3
Grade II hydrocephalus	41	87.7
Hydrocephalus grade III	8	16.3

To establish this scale, the following is required:

- (i) Use the superior axial cut above the third ventricle.
- (ii) Draw a mid-sagittal medial line from the front-occipital inner cranial table and establish an equidistant point between both ends.
- (iii) From this equidistant point, draw a line toward the cranial vault or parietal inner table.
- (iv) Measure the distance on this line between the equidistant point of the sagittal line and the ventricular wall.
- (v) Measure the distance on this line between the equidistant point of the sagittal line and the inner parietal table.
- (vi) Then, this last measurement is divided by five to obtain the value of each segment in successive accumulation from the equidistant point.
- (vii) Ventricular dilation will occupy one of these segments, identified by the measurement from the equidistant point to the ventricular wall.
- (viii) The first segment closest to the equidistant point will always be the segment normal ventricles occupy.
- (ix) The second segment corresponds to hydrocephalus grade I.
- (x) The third segment corresponds to hydrocephalus grade II.
- (xi) The fourth segment corresponds to hydrocephalus grade III.

- (xii) The fifth segment corresponds to hydrocephalus grade IV.
- (xiii) These segments II-III-IV-V correspond to hydrocephalus grades: mild, moderate, severe, and very severe, respectively.
- (xiv) Since the measurement is in millimeters, the same measurement extrapolated to centimeters will be copied (on separate paper) to visualize the extreme measurements of the segment better.
- (xv) If the ventricular wall reaches the proximal half of any segment from grade I to IV, it will be labeled as "initial" hydrocephalus. If it occupies the distal half of the same segment, it will be labeled as "final" hydrocephalus.

All tomographic and pathological examinations must be immediately drawn by the neurosurgeon in the clinical record, indicating the degree of hydrocephalus and whether it is in the initial or final part of that segment (Adakawa, 2022).

For the Evans index, the greatest distance between the frontal horns is taken between the external table distance and the biparietal external table distance. If this exceeds 0.30, we are dealing with hydrocephalus (Maruno *et al.*, 2020; Timmers *et al.*, 2019).

Regarding the distribution of patients according to the cause of obstructive triventricular hydrocephalus, the results show the cause of obstructive triventricular hydrocephalus in the studied patients. It can be observed that aqueductal stenosis was the cause in over half of the patients, accounting for 63.3%, followed by intracranial tumor (14.3%), arachnoid cyst (12.2%), post-infection of the CNS (6.1%), and post-traumatic brain injury (4.1%).

The main causes of obstructive triventricular hydrocephalus reported in the literature are stenosis or obstruction of the Sylvian aqueduct, being the most common cause of congenital hydrocephalus. It results from aqueductal obstruction due to infection, hemorrhage, or tumor. Intraventricular hemorrhage is an acquired form of hydrocephalus that often affects premature babies. Meningitis is inflammation and infection of the membranes (meninges) surrounding and protecting the brain and spinal cord. It can be caused by bacterial or viral infections, which may lead to scarring or fibrosis of the membranes along the pathways of cerebrospinal fluid drainage. Traumatic brain injury, brain tumors in the posterior fossa, and arachnoid cysts, which are congenital and can occur anywhere along the brain, are also causes of obstructive triventricular hydrocephalus (Bridon, 2022; López *et al.*, 2022; Oporto, 2022).

Raouf and colleagues conducted a study to evaluate the efficacy of ETV in treating post-infectious hydrocephalus in a single group of patients. They concluded that the procedure is simple, safe, and effective for treating non-inflammatory etiologies of obstructive hydrocephalus and post-inflammatory hydrocephalus, especially when the aqueduct is obstructed (Yamamoto *et al.*, 2022).

Severe distortion of ventricular anatomy can result from meningitis/ventriculitis with consequent post-infectious hydrocephalus. This distortion often hinders the performance of ETV due to severe adhesions of ependymal structures secondary to ventriculitis, occasionally making the procedure technically impossible. In ideal conditions, CSF should be sterile and have minimal cellularity (Taffin *et al.*, 2020; Toubol *et al.*, 2021).

The most common ventriculoscopic features include yellowish inflammatory exudates, hemosiderin stains on the ependyma, and thickening of the membranes, particularly on the third ventricle floor. Obstruction of the Sylvian aqueduct can be observed due to pus, hemosiderin, or post-infectious ependymal thickening. Almost always present in these cases is ventricular septation, causing multi-septated or multi-compartmental hydrocephalus. These cases require fenestration of the septa to achieve a single communicable ventricle, as a third ventriculostomy does not work in these cases, and a free ventricle is needed to place

a ventriculoperitoneal shunt (Bacigalupe, 2023; Barrera-Lemarchand *et al.*, 2023; Benítez *et al.*, 2023; Ugarte & Trunzo, 2021).

When there is a disorder in CSF absorption at the level of arachnoid villi or damage to venous drainage, ETV will not work since even diverting the flow of CSF from blocked structures; absorption mechanisms may be damaged in some cases of meningitis and ventriculitis or possibly due to underdevelopment of absorption mechanisms (Enríquez-Pérez, 2022; Gómez, 2022).

Table 3 displays the types of complications found in the study. Among the neurological complications identified, a small amount of pneumocephalus predominated in three patients (6.1%), a complication observed in the early cases of the studied series. With improved patient positioning and surgical technique, this complication gradually disappeared in subsequent cases. Intraventricular hemorrhage (2.0%) related to the procedure required an external shunt placement followed by a definitive ventriculoperitoneal shunt, and stoma closure (2.0%) was resolved when the neuroendoscopic technique was repeated for the second time. Extraneurological complications were reported in three patients, with two (5.7%) experiencing respiratory complications, particularly respiratory infections, and one (2.0%) developing a pressure ulcer. Both of these complications were linked to the pathologies causing triventricular hydrocephalus, such as intracranial tumors, where patients had prolonged bed rest, leading to these secondary complications and not directly to the surgical technique itself (Horta & García, 2023; Ibarzábal, 2003; Ron *et al.*, 2023; Torres *et al.*, 2023).

Table 3. Distribution of patients according to types of complications encountered.

Complications		N	%
Neurological	Intraventricular hemorrhage	1	2.0
	Small pneumoencephalus.	3	6.1
	Stoma closure	1	2.0
Extraneurological	Respiratory	2	4.1
	Pressure ulcer	1	2.0

A series of complications related to the surgical procedure have been published, which can be classified as major or minor based on severity. These complications are directly related to the learning curve that neurosurgeons experience with this technique. Recognizing ventricular anatomy, orienting within the postal (an anatomical landmark), and identifying the targeted elements are crucial. Failing to do so can lead to significant mishaps during the procedure. Among the minor complications reported are mild bleeding, which can be controlled with irrigation; trapped air, which may cause postoperative dizziness, nausea, and headaches; non-infectious postoperative fever; and delayed awakening from anesthesia (Lescalle-Ortiz *et al.*, 2022). Major complications include severe bleeding due to rupture of a septal or thalamostriate vein, which may require converting endoscopy into craniotomy to control the injured structures; basilar artery trauma, post-traumatic aneurysms, penetration of parenchymal structures, and subdural hematomas. Jones described aborted ETVs due to bleeding that hinders premaxillary fenestration, causing intraoperative bradycardia. This complication, also described by Handler, results from excessive irrigation, leading to intracranial hypertension and reflex bradycardia (Lundar & Due-Tønnessen, 2021; Mijderwijk *et al.*, 2019; Ujjan *et al.*, 2022).

In a series of 173 consecutive neuroendoscopies by Teo *et al.*, 7% of complications with varying degrees of hypothalamic trauma were reported, including diabetes insipidus, hyperphagia, polydipsia, and amenorrhea. Similarly, 13% of controlled minor complications

were reported (Carestia *et al.*, 2023; Matos-Rodríguez *et al.*, 2023). The use of stereotactic guides, as well as neuronavigation, enhances technique efficiency and reduces complications. Jones reported only 5% morbidity with no mortality when combining stereotaxy with endoscopy in a single procedure. Mortality rates are lower than 2%. The most feared complication is the injury of a major arterial vessel, resulting in rapid and profuse hemorrhage, clouding vision, and preventing coagulation (Alieva *et al.*, 2022; Debs *et al.*, 2021).

In most cases, this is fatal. Procedure-associated morbidity varies and mostly relates to the patient's condition and the surgeon's experience. It includes intraventricular and parenchymal bleeding, infection, transient paralysis of oculomotor cranial nerves, midbrain lesions, confusion attributed to fornix injury, asymptomatic subdural hematomas, and acute subdural hematomas (Sembay & Macedo, 2022). Delayed awakening from anesthesia can occur due to ionic changes in CSF or manipulation of the hypothalamus, as well as respiratory depression due to very cold irrigation solutions that affect chemosensitive brain structures. Postoperative CSF leaks, commonly seen in infants, can occur and should be avoided by ensuring a tight closure. Ventriculitis, whether secondary to a CSF leak or intraoperative contamination, should be considered for early diagnosis and specific treatment due to its severity (Cardoza *et al.*, 2023; Catrambone & Ledwith, 2023; González *et al.*, 2022; Moreno *et al.*, 2022; Sargentón-Savon *et al.*, 2023).

Procedure failures are attributed to tumor progression, reduced CSF reabsorption capacity, ventriculostomy closure in patients with low pressure, or reduced flow through partially functioning shunt systems. Failures can also occur in high protein and fibrinogen concentration cases, as in cases of infection or post-ventricular bleeding. Fukuhara found that preoperative infections are a high-risk factor for third ventriculocisternostomy failure, as only 11.1% of patients with meningitis remained symptom-free after five years of follow-up (Al-Hakim *et al.*, 2019; Choudhary *et al.*, 2020; Gonzalez-Argote, 2022; Mbaye *et al.*, 2020).

Advancements in anatomical knowledge of the ventricular system, understanding of its three-dimensionality, and improved imaging techniques and virtual reality will soon make neuroendoscopy a rapid, risk-free, and highly efficient intervention for controlling conditions where it is formally indicated (Aleem Ragab *et al.*, 2023).

Table 4 shows the postoperative clinical evaluation in patients operated for triventricular obstructive hydrocephalus by neuroendoscopy, evaluating as favorable when the clinical manifestations present before surgery were reversed, as unfavorable when their symptoms and signs did not improve, and as stationary those patients who maintained the same characteristics of their symptoms and signs. In the sample of forty-nine patients at seven days, forty-three patients evolved favorably (87.8 %), five with a stationary evolution of their symptoms and clinical signs (10.2 %), and only one evolved unfavorably (2.0%) due to intraventricular hemorrhage for which he underwent external shunting and then definitive ventriculoperitoneal shunting. Of these five patients with stationary evolution at seven days during follow-up, one underwent a second TVE due to stoma closure, and the remaining four underwent a definitive ventriculoperitoneal shunt. The clinical evaluation at 3 months was favorable in forty-four patients (89.8 %) and five with unfavorable evolution (10.2 %) requiring a ventriculoperitoneal shunt system placement.

Postoperative evaluation includes clinical and imaging aspects. Clinical efficiency is evaluated with the remission of signs and symptoms secondary to endocranial hypertension (Díaz-Chieng *et al.*, 2022; Figueroa *et al.*, 2023; Sánchez *et al.*, 2022; Sebo *et al.*, 2023; Zhang, 2022).

Table 4. Postoperative clinical assessment at seven days and three months.

	7 days		3 months	
	N	%	N	%
Favorable	43	87.8	44	89.8
Unfavorable	1	2.0	5	10.2
Stationary	5	10.2	-	-
Total	49	100	49	100

Table 5 presents the radiological evaluation of patients operated on for obstructive triventricular hydrocephalus using neuro endoscopy. At seven days, forty-one patients showed favorable evolution (83.7%), seven remained stable (14.3%), and only one showed unfavorable outcomes (2.0%). Among these forty-nine patients followed up and subjected to imaging studies at three months, forty-four exhibited favorable outcomes (89.8%), while five had unfavorable outcomes (10.2%) and required definitive ventriculoperitoneal shunt placement.

Radiological assessment should be conducted cautiously, as the percentage of patients showing improvement in ventricular size is low, and conversely, there might be radiological improvement without clinical improvement. When there is suspicion of procedure failure, the gap's persistence in the third ventricle floor is evaluated using non-invasive dynamic CSF studies like cine MRI or transfontanelar ultrasound. Cases have been described where hydrocephalic symptoms reappeared several months after the third ventriculostomy due to total or partial obstruction of the floor caused by neof ormation of membranes (Cano *et al.*, 2023; Gupta, 2022; Kumar *et al.*, 2023; Vallejo, 2023). Radiological Criteria Suggested by Cinalli in 2004 for Good Results:

- (i) Reduction of ventricular size between 10% and 50% on the seventh day.
- (ii) Disappearance of periventricular edema.
- (iii) Preoperative studies show a bulging third ventricle floor, which becomes linear after surgery.
- (iv) Diverticula disappear in the postoperative period.

Grooves and cerebral convolutions, previously obscured by cerebral compression, become visible.

Table 5. Postoperative imaging evaluation at the first seven days and three months applying the Cinalli 2004 criteria.

	7 days		3 months	
	N	%	N	%
Favorable	41	83.7	44	89.8
Unfavorable	1	2.0	5	10.2
Stationary	7	14.3	-	-
Total	49	100	49	100

There is literature suggesting that the most important imaging study for evaluating the effectiveness of ETV in the postoperative period is cine MRI with contrast (55, 60, 65, 66). A new technique called 3DSPACE has been developed based on the T2 sequence of MRI with 3D reconstructions. This technique provides information about CSF circulation, differentiating between stagnant and circulating CSF. Flow dynamics can be detected, particularly at the ventricular level (Grover *et al.*, 2022). These data are used for patient evaluation pre-and postoperatively. Images obtained using 3DSPACE can be reconstructed in any desired plane, providing physiological and morphological data. In analyzing the outcome of

neuroendoscopic treatment in obstructive triventricular hydrocephalus, ETV was successful in forty-four patients (89.8%), while only five patients (10.2%) experienced failure. One patient underwent external shunt placement due to intraventricular hemorrhage and later definitive ventriculoperitoneal shunt placement. Four patients underwent ventriculoperitoneal shunt placement during follow-up.

This result was also evaluated using the Glasgow Outcome Scale, with 100% of cases showing good recovery. ETV efficacy was assessed considering clinical and radiological criteria. The ETV is considered a failure if additional surgical measures are needed due to symptom recurrence or unresolved symptoms (Moreno & Castro, 2022). A satisfactory outcome involves sustained clinical improvement throughout the follow-up without requiring additional surgery. Radiological improvement is also included in the result evaluation, coinciding with authors who incorporate imaging criteria for evaluation. Wellons includes reduction of ventricular size in criteria for a satisfactory outcome. Brockmeyer specifies in the same context that ventricles can maintain the same size or decrease. Cinalli includes the absence of radiological signs of active hydrocephalus to deem endoscopic ventriculostomy effective (Salem-Memou *et al.*, 2020).

Several factors contribute to intervention failure, categorized into two groups. In group one, technique-related factors include the size of the ventriculostomy and the lateral location of the ventriculostomy. For the second group, patient-related factors related to

- (i) Etiology of hydrocephalus.
- (ii) History of CNS infection.
- (iii) Presence of dense arachnoid adhesions in the basal cisterns.
- (iv) Intraparenchymal or subarachnoid hemorrhage.
- (v) Holocranial radiotherapy.
- (vi) Malignant tumors.

Indicators of early ventriculostomy failure include CSF fistula formation and lack of ventricular volume reduction three months after treatment. Revision and, if necessary, new ventriculostomy have been reported in the literature with a high success rate (90%) when appropriately indicated. In this series of forty-nine patients, only one case was detected with stoma closure and no clinical improvement at the 3-month evaluation. A second ETV was performed with satisfactory results. This outcome corresponds to a study conducted at the Prof. Dr. R. Rossi Hospital Neurosurgery Service in La Plata, Argentina, where 14.2% of 140 patients required a second ETV due to failure of the initial procedure. Given the low rates of mortality and morbidity associated with the procedure and its potential benefits for the patient, it is recommended that, in the event of ventriculostomy failure and following a thorough analysis of the indication, endoscopic exploration and, if ventriculostomy obstruction is found, the procedure be repeated to capitalize on the benefits of shunt independence (Sánchez, 2023).

In a study by Romero *et al.*, preoperative and transoperative risk factors were analyzed, and an intraoperative scale was suggested to predict ETV failure. Factors identified included:

- (i) Abnormal ventricular anatomy.
- (ii) Intraoperative incidents.
- (iii) Opening the Lilliequist membrane in a secondary endoscopic maneuver.
- (iv) Thickened or multiple membranous structures in the subarachnoid space.
- (v) Absence or weakness of pulsations on the floor of the third ventricle after ETV completion.
- (vi) Need for coagulation of the premaxillary membrane edges.

In forty-two patients, hospital stays did not exceed 7 days (85.7%), five patients stayed for 7 to 14 days (10.2%), and only two stayed for more than 14 days (4.1%). In most cases, minimally invasive surgical techniques reduce hospital stays, which is closely related to the economic costs of extended hospitalization. In the studied series, longer hospital stays of 7 to 14 days or more than 14 days were associated with the cause of obstructive triventricular hydrocephalus, specifically intracranial tumors, and not with the neuro endoscopic procedure itself. This study gives additional information regarding medical and health science. Indeed, this will bring more information for further research in medical and health science as reported in previous reports (Ahsan *et al.*, 2021; Ahsan *et al.*, 2022a; Ahsan *et al.*, 2022b; Ahsan *et al.*, 2022c; Ahsan, 2023; Rana *et al.*, 2022).

4. CONCLUSION

Of the 49 patients with triventricular obstructive hydrocephalus who underwent EVT, the predominant age group was under 20, and the patients were male. Among the clinical symptoms and imaging signs that mostly occurred in these patients were headache, vomiting, and papilledema, accompanied by dilatation of the lateral ventricles and III ventricle, with Evans index greater than 0.30 and decreased subarachnoid space. Of the causes of triventricular obstructive hydrocephalus, stenosis of the aqueduct of Sylvius was the most frequent in these patients, followed by brain tumors, this cause being related to four of the five patients in whom TVE failed, with the need for definitive ventriculoperitoneal shunting. Small pneumocephalus was the most common neurological complication. In general, the outcome of TVE in patients operated on with triventricular hydrocephalus of obstructive cause in their clinical and postoperative imaging evaluation was successful with a good recovery in 44 patients which constituted 89.8 % of the cases. The hospital stay is also significantly reduced, which brings a lower possibility of nosocomial infections, lower hospitalization costs, and faster incorporation of the patient into his normal life. Endoscopic procedures are an alternative technique with advantages over conventional techniques in that they are fast, safe, and effective.

5. AUTHORS' NOTE

The authors declare that there is no conflict of interest regarding the publication of this article. The authors confirmed that the paper was free of plagiarism.

6. REFERENCES

- Adakawa, M. I. (2022). Relevance of Akerloff's theory of information asymmetry for the prevention and control of zoonotic infectious diseases in Sub-Saharan Africa: Perspective of Library and Information Services Provision. *Advanced Notes in Information Science*, 1, 31-58.
- Ahsan, M. (2023). Nutrition and dietetics concerning diabetes mellitus: Gestational diabetes mellitus. *ASEAN Journal of Agricultural and Food Engineering*, 2(2), 45-52.
- Ahsan, M., Tasleem, M.W., Rajpoot, S.R., Ayub, H.M., Ahmad, M., Irshad, Q., and Kanwal, T. (2022a). Effect of onion peel tea supplementation and exercise against hypercholesterolemia and cardiovascular risk factors in obese women: Education and randomized control trial. *Indonesian Journal of Multidisciplinary Research*, 2(1), 159-168.

- Rana, Z.A., Ahsan, M., Ali, M., Atif, A., and Uzair, M. (2022). Food preferences and nutritional status: Insights on nutrition transition in university community. *Indonesian Journal of Multidisciplinary Research*, 2(1), 169-178.
- Ahsan, M., Raza, H., Ali, S., and Raza, M.H. (2021). Predictors of polio immunization hesitancy: A cross-sectional study from Mardan Pakistan. *ASEAN Journal of Science and Engineering Education*, 2(1), 199-212.
- Ahsan, M., Uzair, M., and Ali, M. (2022b). Attitudes and perceptions towards cultured meat among general population in Pakistan. *ASEAN Journal of Science and Engineering Education*, 2(1), 111-122.
- Ahsan, M., Anwer, K., Raza, H., Ali, S., Ali, M., and Akhter, P. (2022c). Knowledge, perceptions, and attitudes towards dementia among medical students in Pakistan. *Indonesian Journal of Community and Special Needs Education*, 2(1), 29-38.
- Ahsan, M. (2022). Nutrition and dietetics concerning diabetes mellitus: Type 1 diabetes mellitus. *ASEAN Journal of Agricultural and Food Engineering*, 1(1), 37-44.
- Aleem Ragab, O. A., Fathalla, H., El halaby, W., Maher, W., Hafez, M., and Zohdi, A. (2023). Spontaneous third ventriculostomy in cases of aqueductal stenosis: A retrospective case series. *World Neurosurgery*, 176, e408-e414.
- Al-Hakim, S., Schaumann, A., Tietze, A., Schulz, M., and Thomale, U.-W. (2019). Endoscopic third ventriculostomy in children with third ventricular pressure gradient and open ventricular outlets on MRI. *Child's Nervous System*, 35(12), 2319-2326.
- Alieva, K., Kokhraidze, N. A., and Ulrikh, E. A. (2022). 107 The onco-hematological patient from the adolescent gynecologist's point of view: Main aspects and clinical examples. *European Journal of Obstetrics and Gynecology and Reproductive Biology*, 273, e45.
- Apra, C., Penet, N., and Froelich, S. (2019). Cerebrospinal fluid fistula in the frontal sinus secondary to obstructive hydrocephalus. *World Neurosurgery*, 131, 19-20.
- Bacigalupe, M. de los A. (2023). Emociones y movimiento en el estudio inter(trans)disciplinario del comportamiento humano desde dentro. *Salud, Ciencia y Tecnología-Serie de Conferencias*, 2(1), 83-83.
- Barrera-Lemarchand, F., Lescano-Charreau, V., Ruiz, J., Cáceres, N., and Navajas, J. (2023). "Menos es Más" el impacto de la complejidad discursiva en la valoración de argumentos morales. *Salud, Ciencia y Tecnología - Serie de Conferencias*, 2(1), 1-3.
- Becerra, Y. D., and Páez, S. C. (2022). Sepsis neonatal, manejo y prevención. *Salud, Ciencia y Tecnología - Serie de Conferencias*, 1(1), 1-2.
- Benítez, M. A., Shifres, F., and Justel, N. (2023). La relación de la educación musical con las habilidades cognitivas en niñas y niños de 6 a 8 años: Un análisis comparativo entre músicos y no músicos. *Salud, Ciencia y Tecnología - Serie de Conferencias*, 2(1), 1-2.
- Bridon, N. H. (2022). Síndrome obstructivo nasal en pacientes con tratamiento ortodóncico. *Salud, Ciencia y Tecnología*, 2, 68.

- Cano, C. A. G., Castillo, V. S., and Gallego, T. A. C. (2023). Unveiling the thematic landscape of generative pre-trained transformer (GPT) through bibliometric analysis. *Metaverse Basic and Applied Research*, 2, 33.
- Cardoza, W., Rodriguez, C., Pérez-Galavís, A., and Ron, M. (2023). Work psychosocial factors and stress in medical staff in the epidemiology area of a public institution. *Interdisciplinary Rehabilitation / Rehabilitacion Interdisciplinaria*, 3, 52.
- Carestia, D. R., Beltran, A. F., Cerdera, F., Sanchez, M. L., and Ibáñez, F. (2023). Impacto fisiológico de la respiración, en la salud y en el nivel del estrés. *Interdisciplinary Rehabilitation / Rehabilitacion Interdisciplinaria*, 3, 46.
- Catrambone, A. R., and Ledwith, A. S. (2023). Acompañamiento interdisciplinar de las trayectorias académicas, en formación docente y psicopedagógica. *Salud, Ciencia y Tecnología - Serie de Conferencias*, 2(1), 1-2.
- Choudhary, A., Sobti, S., Zambre, S., and Bhaskar, S. (2020). Endoscopic third ventriculostomy in failed ventriculoperitoneal shunt in pediatric population. *Asian Journal of Neurosurgery*, 15(4), 937-940.
- Cuétara, L. H., Pupo, D. T. P., Queija, Y. F., and Pérez, I. L. (2021). Cronología y secuencia de erupción dentaria permanente en niños de 5 a 12 años. *Salud, Ciencia y Tecnología*, 1, 23.
- Debs, L. H., Rahimi, S. Y., Rutkowski, M. J., and Macomson, S. D. (2021). Endoscopic third ventriculostomy may decrease shunt-dependency in patients with post-hemorrhagic hydrocephalus following aneurysmal subarachnoid hemorrhage. *Interdisciplinary Neurosurgery*, 26, 101300.
- Diaz, B. C., and Albanese, E. S. (2023). Condiciones éticas para la investigación con personas mayores. Una revisión narrativa. *Salud, Ciencia y Tecnología*, 3, 219.
- Díaz-Chieng, L. Y., Auza-Santiváñez, J. C., and Castillo, J. I. R. (2022). The future of health in the metaverse. *Metaverse Basic and Applied Research*, 1, 1.
- Enríquez-Pérez, E. (2022). Acercamiento al manejo del traumatismo craneoencefálico severo en pacientes pediátricos. *Salud, Ciencia y Tecnología - Serie de Conferencias*, 1(1), 1.
- Figueroa, R. C., Correa, G. C., and Gomez, S. del R. P. (2023). Statistical analysis of social networks as a means of communication for children in educational institutions in Riohacha, La Guajira, Colombia. *Metaverse Basic and Applied Research*, 2, 53.
- Gómez, M. M. C. (2022). Análisis de los factores que influyen en el cese de la lactancia materna exclusiva. *Salud, Ciencia y Tecnología - Serie de Conferencias*, 1(2), 2.
- González, M. E., Alfonso, A. P., Ramos, O. D., Horta, Y. R., Carrera, Y. R., and Pita, Y. L. (2022). Factores biopsicosociales de discapacidad en adultos mayores. *Interdisciplinary Rehabilitation / Rehabilitacion Interdisciplinaria*, 2, 19.
- Gonzalez-Argote, J. (2022). Calidad del Sueño: Factor Clave en la Recuperación Física y Mental de Estudiantes de Medicina. *Interdisciplinary Rehabilitation / Rehabilitacion Interdisciplinaria*, 2, 21.

- Grover, S., Gupta, B. M., Ahmed, K. K. M., and Kappi, M. (2022). A scientometric research of high-cited publications in obsessive-compulsive disorders during 2012-2021. *Iberoamerican Journal of Science Measurement and Communication*, 2(3), 3.
- Gupta, B. (2022). Understanding blockchain technology: How it works and what it can do. *Metaverse Basic and Applied Research*, 1, 18.
- Hidalgo, G. M. A., González, A. F. M., Idrovo, A. C. Y., and Flores, P. M. F. (2022). Diagnóstico de displasia de cadera en recién nacidos. *Salud, Ciencia y Tecnología*, 2, 182-182.
- Hochstetler, A., Raskin, J., and Blazer-Yost, B. L. (2022). Hydrocephalus: Historical analysis and considerations for treatment. *European Journal of Medical Research*, 27(1), 168.
- Horta, G. A. H., and García, Z. G. (2023). Resultados del tratamiento de rehabilitación física en niños con retardo en el desarrollo psicomotor. *Interdisciplinary Rehabilitation / Rehabilitacion Interdisciplinaria*, 3, 28.
- Ibarzábal, F. A. (2003). Aspectos emocionales y calidad de vida en pacientes con enfermedades desmielinizantes: El caso de la esclerosis múltiple. *Anales de Psicología / Annals of Psychology*, 19(1), 1.
- Jiménez, T. F. de, Fernández, R. C. J., and Auza-Santiváñez, J. C. (2022). Hemangioma congénito múltiple sobreinfectado en zona escrotal: Reporte de caso. *Salud, Ciencia y Tecnología*, 2, 173-173.
- Jurado, H. A. R., Cedeño, A. M. Q., Gallegos, M. C. P., Jurado, E. A. R., Mosquera, L. C. P., Godoy, E. P. G., Medina, L. M. D., Castillo, J. U. P., and Zea, M. A. C. (2023). Evaluación de la atención pediátrica en contextos de atención primaria de la salud: Un estudio observacional. *Salud, Ciencia y Tecnología*, 3, 374.
- Kahle, K. T., Kulkarni, A. V., Limbrick, D. D., and Warf, B. C. (2016). Hydrocephalus in children. *The Lancet*, 387(10020), 788-799.
- Karimy, J. K., Reeves, B. C., Damisah, E., Duy, P. Q., Antwi, P., David, W., Wang, K., Schiff, S. J., Limbrick, D. D., Alper, S. L., Warf, B. C., Nedergaard, M., Simard, J. M., and Kahle, K. T. (2020). Inflammation in acquired hydrocephalus: Pathogenic mechanisms and therapeutic targets. *Nature Reviews Neurology*, 16(5), 5.
- Krejčí, T., Krejčí, O., Mrůzek, M., Röschlová, I., and Lipina, R. (2021). Non-communicating hydrocephalus with a primary empty sella presenting with growth hormone deficiency and delayed puberty successfully treated by endoscopic third ventriculocisternostomy. *Acta Neurochirurgica*, 163(2), 511-514.
- Kumar, D., Haque, A., Mishra, K., Islam, F., Mishra, B. K., and Ahmad, S. (2023). Exploring the transformative role of artificial intelligence and metaverse in education: A comprehensive review. *Metaverse Basic and Applied Research*, 2, 55.
- Lefevre, E., Caudron, Y., Beccaria, K., Levy, R., Dangouloff-Ros, V., Blauwblomme, T., and Boddaert, N. (2023). Reliability of fast-spin echo T2-weighted three-dimensional sequences to predict endoscopic third ventriculocisternostomy patency in children. *Child's Nervous System*, 39(4), 937-942.

- Lescalle-Ortiz, Y. de la C., Cabrera-Mejico, D., Barrios-Ferreiro, G., Portales-Robaina, L., Cordero-Cabrera, Y. de la C., and Echevarría-Sotres, A. (2022). Low birth weight: Cuban scientific production in the Scopus, 2000-2021. *Iberoamerican Journal of Science Measurement and Communication*, 2(3), 3.
- López, V. I. E., Almeida, V. S. Q., Quisimalin, D. E. M., Pérez, G. P. L., Peralta, A. L. J., and Aguilar, T. E. R. (2022). Manejo de neonatos con colangiopatía obstructiva crónica neonatal. Cirugía de Kasai. *Salud, Ciencia y Tecnología*, 2, 246-246.
- Lundar, T., and Due-Tønnessen, B. J. (2021). Fatal Sunt Failure 40 years after Implantation of a lumbouretral shunt in a hydrocephalic infant. *Annals of Urology and Nephrology*, 2021, 1-2.
- Maruno, S., Naito, T., Nakamoto, F. K., Kamisawa, A., Sato, T., Seki, T., Maekawa, R., Hideyama, T., Ushiku, T., Shin, M., and Shiio, Y. (2020). Communicating hydrocephalus associated with neurosarcoidosis diagnosed by endoscopic biopsy. *Neurology and Clinical Neuroscience*, 8(2), 79-81.
- Matos-Rodríguez, A., Sargentón-Savon, S., Mosqueda-Lobaina, Y., and Chibas-Muñoz, E. E. (2023). Características del síndrome demencial en la atención primaria de salud. *Interdisciplinary Rehabilitation / Rehabilitacion Interdisciplinaria*, 3, 45.
- Mbaye, M., Gahito, L., Thiam, A. B., Thioub, M., Sy, E. N., Faye, M., Diop, S., Ndongo, M., Ndoeye, N., Ba, M. C., and Badiane, S. B. (2020). The outcome of endoscopic third ventriculostomy in a mixed population of adult and pediatric patients. *Open Journal of Modern Neurosurgery*, 10(3), 3.
- Mejías, M., Coronado, Y. C. G., and Peralta, A. L. J. (2022). Inteligencia artificial en el campo de la enfermería. Implicaciones en la asistencia, administración y educación. *Salud, Ciencia y Tecnología*, 2, 88.
- Mijderwijk, H.-J., Fischer, I., Zhivotovskaya, A., Bostelmann, R., Steiger, H.-J., Cornelius, J. F., and Petridis, A. K. (2019). Prognostic model for chronic shunt-dependent hydrocephalus after aneurysmal subarachnoid hemorrhage. *World Neurosurgery*, 124, e572-e579.
- Morales, E. J. F., Canaba, C. A. G., Chicaiza, L. B. L., Vaca, D. P. P., Villacres, L. S. M., Córdova, C. A. R., Díaz, H. I. V., Coloma, A. M. R., and Carrera, Á. A. L. (2023). El arte y la ciencia de la cirugía de reconstrucción tumoral pediátrica: Una revisión exhaustiva. *Salud, Ciencia y Tecnología*, 3, 467.
- Moreno, M. C. C., and Castro, G. L. G. (2022). Strengthening governance in Caquetá: The role of web-based transparency mechanisms for public information. *Metaverse Basic and Applied Research*, 1, 16.
- Moreno, Z. V., Ravelo, E. N., Llanes, L. A., Castillo, I. E. S., and Tamargo, Y. C. (2022). Ansiedad, depresión y estrategias de afrontamiento en pacientes convalescentes de Covid-19. *Interdisciplinary Rehabilitation / Rehabilitacion Interdisciplinaria*, 2, 10-10.
- Nakajima, M., Yamada, S., Miyajima, M., Ishii, K., Kuriyama, N., Kazui, H., Kanemoto, H., Suehiro, T., Yoshiyama, K., Kameda, M., Kajimoto, Y., Mase, M., Murai, H., Kita, D., Kimura, T., Samejima, N., Tokuda, T., Kaijima, M., Akiba, C., Kawamura, K., Atsuchi, M., Hirata, Y., Matsumae, M., Sasaki, M., Yamashita, F., Aoki, S., Irie, R., Miyake, H., Kato, T.,

- Mori, E., Ishikawa, M., Date, I., and Arai, H. (2021). Guidelines for management of idiopathic normal pressure hydrocephalus (third edition): Endorsed by the Japanese society of normal pressure hydrocephalus. *Neurologia Medico-Chirurgica*, 61(2), 63-97.
- Novoa-Rojas, F., and Báez-Alarcón, A. (2023). Neuro-tecnologías y códigos cerebrales: La importancia de legislar en clave deconstructiva. *Salud, Ciencia y Tecnología*, 3, 379-379.
- Oliveira, L. M., Nitrini, R., and Román, G. C. (2019). Normal-pressure hydrocephalus: A critical review. *Dementia and Neuropsychologia*, 13, 133-143.
- Oporto, L. N. (2022). Práctica de enfermería basada en la evidencia y prevención de las caídas en pacientes internados. *Salud, Ciencia y Tecnología*, 2, 59-59.
- Pérez, R. C. (2022). Impacto de las lesiones domésticas en la salud pediátrica: Una perspectiva epidemiológica. *Salud, Ciencia y Tecnología - Serie de Conferencias*, 1(2), 2.
- Ramírez, V. A., and Ruetti, E. (2023). Analizando la integración del procesamiento emocional, cognitivo y fisiológico en la etapa preescolar. *Salud, Ciencia y Tecnología - Serie de Conferencias*, 2(1), 1.
- Rodríguez-Portelles, A. C., Rómulo, A. M. C., Flores, D. P. R., Choque, R. C., Arellano, F. P., Millan, E. R., Guachichulca, R., Jaimes, I., and Fernández, M. V. (2023). Comparación del cateterismo venoso central guiado por ultrasonido versus referencias anatómicas en pacientes pediátricos críticos: Un estudio prospectivo. *Salud, Ciencia y Tecnología*, 3, 522.
- Ron, M., Pérez, A., and Hernández-Runque, E. (2023). Nivel de riesgo para la salud y predicción del dolor musculoesquelético en trabajadores en condiciones de teletrabajo: Un enfoque matricial. *Interdisciplinary Rehabilitation / Rehabilitacion Interdisciplinaria*, 3, 40
- Ruiz, J. I. H., Suquilanda, W. A. H., and Torres, Z. K. S. (2023). Incidencia de pacientes pediátricos con enfermedades diarreicas del puesto de salud tres cerritos—Pasaje en el periodo 2020 – 2022. *Salud, Ciencia y Tecnología*, 3, 398-398.
- Salazar, B. R. M., Salazar, L. E. M., Arevalo, J. B. M., Clavijo, C. G. V., and Quiroga, L. A. T. (2023). Desafíos diagnósticos y terapéuticos en un paciente pediátrico con anencefalia, hidrocefalia y epilepsia: Reporte de caso. *Salud, Ciencia y Tecnología*, 3, 359-359.
- Salem-Memou, S., Chavey, S., Elmoustapha, H., Mamoune, A., Moctar, A., Salihi, S., and Boukhrissi, N. (2020). Hydrocephalus in newborns and infants at the nouakchott national hospital. *The Pan African Medical Journal*, 36, 184.
- Saltos, G. D. C., Oyarvide, W. V., Sánchez, E. A., and Reyes, Y. M. (2023). Análisis bibliométrico sobre estudios de la neurociencia, la inteligencia artificial y la robótica: Énfasis en las tecnologías disruptivas en educación. *Salud, Ciencia y Tecnología*, 3, 362-362.
- Sánchez, C. M. C., León, L. A. G., Yanes, R. C. A., and Oloriz, M. A. G. (2022). Metaverse: The future of medicine in a virtual world. *Metaverse Basic and Applied Research*, 1, 4-4.
- Sánchez, R. M. (2023). Vídeos 360° como herramienta de entrenamiento de habilidades sociales con alumnado TEA. *Metaverse Basic and Applied Research*, 2, 34-34.

- Sargentón-Savon, S., Matos-Rodríguez, A., Mosqueda-Lobaina, Y., and Chibas-Muñoz, E. E. (2023). Factores biopsicosociales que influyen en los cuidadores principales de pacientes con diagnóstico de síndrome demencial. *Interdisciplinary Rehabilitation / Rehabilitacion Interdisciplinaria*, 3, 47-47.
- Sebo, T. A. R., Oentarto, A. S. A., and Situmorang, D. D. B. (2023). "Counseling-Verse": A survey of young adults from faith-based educational institution on the implementation of future mental health services in the metaverse. *Metaverse Basic and Applied Research*, 2, 42.
- Sembay, M. J., and Macedo, D. D. J. de. (2022). Health information systems: Proposal of a provenance data management method in the instantiation of the W3C PROV-DM model. *Advanced Notes in Information Science*, 2, 192-201.
- Silva, M. L., Gasparini, M. V., Stahringer, G., Escher, L., Iacobuzio, S., Rubbo, Y., Tenaglia, M. F., Frontini, M. G., and Isely, C. I. (2023). Interdisciplinariedad en el diseño de instrumentos de evaluación: La Batería ecológica de evaluación de funciones cognitivas y lingüística. *Salud, Ciencia y Tecnología - Serie de Conferencias*, 2(1), 1.
- Sulibele, U. S. U., Prajapati, S., and Desai, M. (2023). Efectos de la simulación colaborativa en la seguridad del paciente en la educación médica. *Salud, Ciencia y Tecnología*, 3, 457-457.
- Taffin, H., Maurey, H., Ozanne, A., Durand, P., Husson, B., Knebel, J.-F., Adamsbaum, C., Deiva, K., and Saliou, G. (2020). Long-term outcome of vein of Galen malformation. *Developmental Medicine and Child Neurology*, 62(6), 729-734.
- Tandon, P. N. (2021). Hydrocephalus: A historical perspective down the memory lane. *Neurology India*, 69(8), 259.
- Tiban, P. A. C., and Coronado, Y. C. G. (2023). Cuidado humanizado de enfermería en pacientes hospitalizados. *Salud, Ciencia y Tecnología*, 3, 260-260.
- Timmers, A. A. C., Bos, E. M., and Dammers, R. (2019). A case of spontaneous third ventriculocisternostomy to the interpeduncular fossa. *World Neurosurgery*, 127, 530-533.
- Torres, A., Pérez-Galavís, A., Ron, M., and Mendoza, N. (2023). Factores psicosociales laborales y estrés en el personal médico asistencial. *Interdisciplinary Rehabilitation / Rehabilitacion Interdisciplinaria*, 3, 42-42.
- Toubol, A., Baroncini, M., Kuchcinski, G., Poidevin, P., Vandendriessche, D., and Lejeune, J.-P. (2021). Mis-diagnosed giant ovarian cyst and ventriculoperitoneal shunt malfunction. *Neurochirurgie*, 67(2), 198-200.
- Ugarte, V. B., and Trunzo, C. G. (2021). Organización y gestión de enfermería en la práctica de extracción de muestras sanguínea. *Salud, Ciencia y Tecnología*, 1, 26-26.
- Ujjan, B. U., Nawaz, S., Anwer, M. S., Rehman, S., Kamran, M., and Hassan, N. (2022). Prevalence and pattern of initial complications following endoscopic third ventriculostomy for hydrocephalus obstructor. *Pakistan Journal of Medical and Health Sciences*, 16(12), 12.

- Vallejo, R. G. (2023). Análisis de la traducción automática en los estudios sobre metaverso. *Metaverse Basic and Applied Research*, 2, 38-38.
- Verdesoto, G. J. Z., Soto, I. B. R., and Alfaro, A. C. (2023). Aportes de las neurociencias, neuromarketing y procesos de aprendizaje en innovación. *Salud, Ciencia y Tecnología*, 3, 396-396.
- Wang, Z., Zhang, Y., Hu, F., Ding, J., and Wang, X. (2020). Pathogenesis and pathophysiology of idiopathic normal pressure hydrocephalus. *CNS Neuroscience and Therapeutics*, 26(12), 1230-1240.
- Yamamoto, T., Takeuchi, K., Nagata, Y., Mizuno, A., Harada, H., and Saito, R. (2022). A novel endoscopic ventriculocisternostomy and stenting technique with a transparent acrylic puncture needle for a trapped temporal horn: A technical report and literature review. *Neurosurgical Review*, 45(2), 1783-1789.
- Zhang, W. (2022). Blockchain-based solutions for clinical trial data management: A systematic review. *Metaverse Basic and Applied Research*, 1, 17-17.